

Case report

Open Access

Vestibular schwannoma with contralateral facial pain – case report

Behzad Eftekhar*, Mohammadreza Gheini, Mohammad Ghodsi and Ebrahim Ketabchi

Address: Department of Neurosurgery and Neurology, Sina Hospital, Tehran University, Iran

Email: Behzad Eftekhar* - eftekhar@sina.tums.ac.ir; Mohammadreza Gheini - gheini@sina.tums.ac.ir; Mohammad Ghodsi - ghodsism@sina.tums.ac.ir; Ebrahim Ketabchi - ketabchi@sina.tums.ac.ir

* Corresponding author

Published: 21 March 2003

Received: 23 November 2002

BMC Neurology 2003, **3**:2

Accepted: 21 March 2003

This article is available from: <http://www.biomedcentral.com/1471-2377/3/2>

© 2003 Eftekhar et al; licensee BioMed Central Ltd. This is an Open Access article: verbatim copying and redistribution of this article are permitted in all media for any purpose, provided this notice is preserved along with the article's original URL.

Abstract

Background: Vestibular schwannoma (acoustic neuroma) most commonly presents with ipsilateral disturbances of acoustic, vestibular, trigeminal and facial nerves. Presentation of vestibular schwannoma with contralateral facial pain is quite uncommon.

Case presentation: Among 156 cases of operated vestibular schwannoma, we found one case with unusual presentation of contralateral hemifacial pain.

Conclusion: The presentation of contralateral facial pain in the vestibular schwannoma is rare. It seems that displacement and distortion of the brainstem and compression of the contralateral trigeminal nerve in Meckel's cave by the large mass lesion may lead to this atypical presentation. The best practice in these patients is removal of the tumour, although persistent contralateral pain after operation has been reported.

Background

Vestibular schwannoma (acoustic neuroma) most commonly presents with ipsilateral disturbances of acoustic, vestibular, trigeminal and facial nerves [5]. Contralateral trigeminal nerve dysfunction as a false localizing sign in acoustic neuroma has been documented [3,6,7]. Contralateral facial pain presenting as trigeminal neuralgia has been mentioned as false localizing sign for posterior fossa and cerebellopontine angle tumors [1,10,4,2]. However presentation of the vestibular schwannoma with contralateral facial pain is quite uncommon. Among 156 patients with vestibular schwannoma who underwent surgery at Sina hospital during past 6 years, we encountered one case with this unusual presentation.

Case presentation

A 44-year old woman presented with one month history of right hemifacial pain, ataxia, progressive vertigo and

left sided hearing loss. She described the pain as burning and constant without any relation to a specific position or movement. The pain had started gradually, and had become increasingly annoying. The patient had sought medical consultation mainly for her facial pain. Physical examination revealed mild left facial paresis. The right of her face was dysesthetic in territories of all three subdivisions of trigeminal nerve. Her cerebellar tests were abnormal on the left side. She also had left sided hearing loss and hypoactive corneal reflexes on both sides. MRI studies with and without contrast showed a giant (45 × 44 × 42 mm) left cerebellopontine angle nonhomogenous mass compatible with a vestibular schwannoma (Fig. 1). The rostral and medial extension of the tumour and distortion of the brainstem was remarkable in this case. The patient was operated upon by retrosigmoid approach in sitting position. Pathologic examination of the tumour confirmed the preoperative diagnosis of vestibular

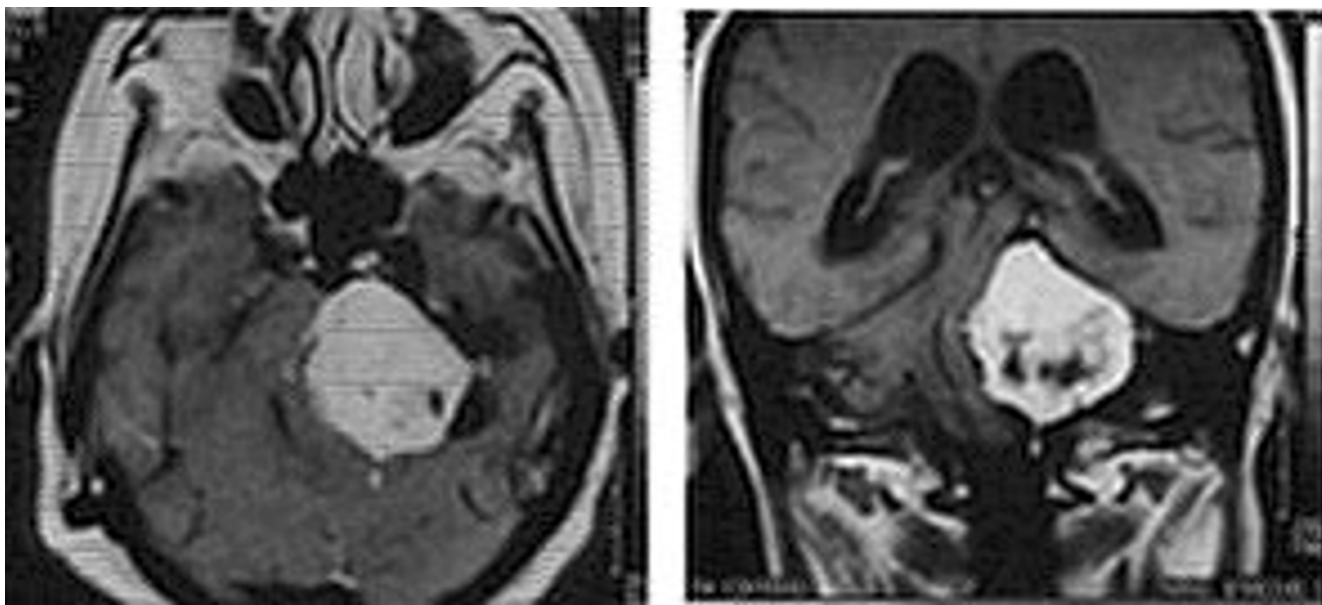


Figure 1
In her MRI with contrast, a giant (45 × 44 × 42 mm) left CP angle nonhomogenous mass compatible with vestibular schwannoma is seen. The rostral and medial extension of the tumour and distortion of the brainstem is notable.

schwannoma. Postoperatively (Fig. 2) her right hemifacial pain was relieved and her corneal reflexes returned to normal activity. The left facial nerve function could not be preserved.

Discussion

Contralateral facial pain associated with cerebellopontine angle and posterior fossa tumors has been attributed to different reasons such as the tumor size and displacement of the brainstem, angulations and distortion of the nerve roots, anatomic variation of posterior fossa, the relationships of cranial nerves and nearby blood vessels and the compression of the contralateral trigeminal nerve in Meckel's cave by the tumor [2,6]. In this report we present a vestibular schwannoma with constant contralateral trigeminal pain. The very early report by Snow and Frazer [10] on a vestibular schwannoma described tic doloieux. Samii and Matthies reported the increased incidence of vascular compression pain in ipsilateral tumors, namely vestibular schwannomas [8]. Sepehrnia and Schulte reported a case of contralateral neuralgia caused by a meningioma [9]. The constant presence of the pain is not typical of a vascular compression syndrome. We did not identify any vascular abnormality around the trigeminal nerve in high-resolution MR images. The main cause of pain in our case seems to be displacement and distortion of the brainstem and less probably compression of the

contralateral trigeminal nerve in Meckel's cave by the tumor.

In some patients, removing of the tumor results in relief of contralateral pain. This seems to be due to return of the brainstem to its normal position and reversing the contralateral pain producing mechanism, as has happened with our case. Persistent contralateral pain after removal of the contralateral posterior cranial fossa tumor has been attributed to arachnoid adhesions and arterial loops [2].

Conclusion

Contralateral facial pain is a rare presentation of the giant vestibular schwannomas. The causative mechanism is most probably displacement and distortion of the brainstem and less probably compression of the contralateral trigeminal nerve in Meckel's cave by the large mass lesion. The best practice in these patients is removal of the tumour, although persistent contralateral pain after operation has been reported.

Acknowledgement

We thank Dr. Mehdi Nassiri Fellow in Hematopathology, University of Miami, Florida for his comments and help. Written consent was obtained from the patient for publication of the patient's details.

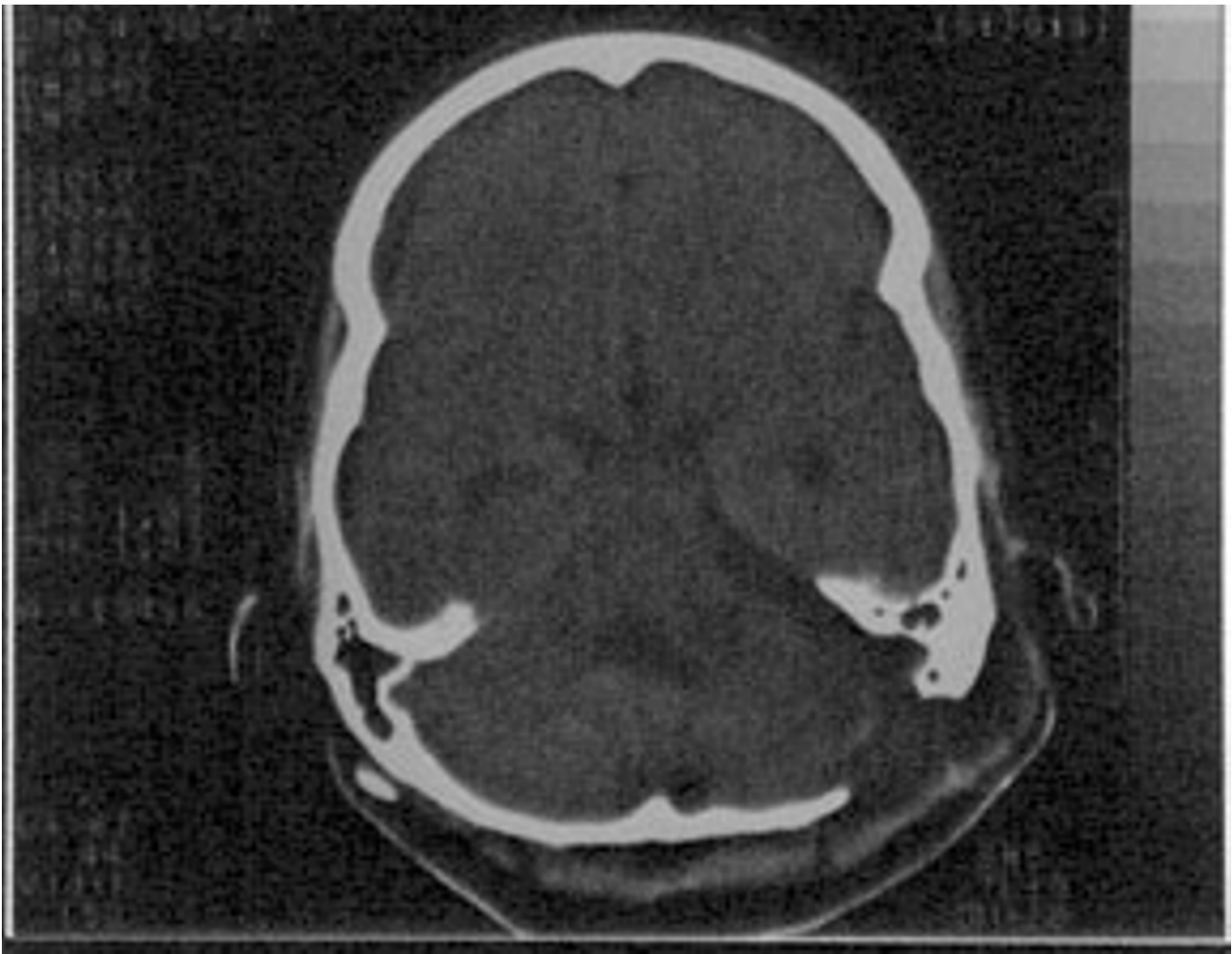


Figure 2

Postoperatively, the tumour is totally removed and place of the craniectomy is seen. The brainstem seems to be returned to rather normal position.

References

1. Florensa R, Llovet J, Pou A, Galito E, Vilato J and Colet S **Contralateral trigeminal neuralgia as a false localizing sign in intracranial tumors** *Neurosurgery* 1987, **20**(1):1-3
2. Grigoryan YA and Onopchenko CV **Persistent Trigeminal Neuralgia after Removal of the Contralateral Posterior Cranial Fossa Tumor. Report of Two Cases** *Surg Neurol* 1999, **52**:56-61
3. Koenig M, Kalyan-Raman K and Sureka ON **Contralateral trigeminal nerve dysfunction as a false localizing sign in acoustic neuroma: a clinical and electrophysiological study** *Neurosurgery* 1984, **14**(3):335-7
4. Marco Igual M, Dalmau Obrador J, Aguilar Barbera M and Bartomeus Gene F **Trigeminal neuralgia and neurinoma of the contralateral acoustic nerve** *Med Clin (Barc)* 1985, **85**(14):601
5. Matthies C and Samii M **Management of 1000 vestibular schwannomas (acoustic neuromas) : Clinical Presentation** *Neurosurgery* 1997, **40**(1):1-10
6. Ro LS, Chen ST, Tang LM and Wei KC **Concurrent trigeminal, abducens, and facial nerve palsies presenting as false localizing signs: case report** *Neurosurgery* 1995, **37**(2):322-4
7. Salazar JA, Diaz Espejo C, Robledo Strauss A and Gil Neciga E **Acoustic neurinoma and disease of the contralateral nerve pair V** *Neurologia* 1989, **4**(6):222-3
8. Samii M and Matthies C **Acoustic neurinomas associated with vascular compression syndromes** *Acta Neurochirurgica* 1995, **134**:148-154
9. Sepehrnia A and Schulte Th **Trigeminal neuralgia caused by contralateral cerebellopontine angle meningioma – case report** *Zentralblatt Neurochir* 2001, **62**(2):62-64
10. Snow RB and Fraser RA **Cerebellopontine angle tumor causing contralateral trigeminal neuralgia: a case report** *Neurosurgery* 1987, **21**(1):84-6

Pre-publication history

The pre-publication history for this paper can be accessed here:

<http://www.biomedcentral.com/1471-2377/3/2/prepub>

Publish with **BioMed Central** and every scientist can read your work free of charge

"BioMed Central will be the most significant development for disseminating the results of biomedical research in our lifetime."

Sir Paul Nurse, Cancer Research UK

Your research papers will be:

- available free of charge to the entire biomedical community
- peer reviewed and published immediately upon acceptance
- cited in PubMed and archived on PubMed Central
- yours — you keep the copyright

Submit your manuscript here:
http://www.biomedcentral.com/info/publishing_adv.asp

